

Advance Publication by J-STAGE

Japanese Journal of Infectious Diseases

Spontaneous non-traumatic *Clostridium perfringens* sepsis

Toru Hifumi

Received: September 10, 2019. Accepted: December 4, 2019

Published online: December 25, 2019

DOI:10.7883/yoken.JJID.2019.382

Advance Publication articles have been accepted by JJID but have not been copyedited or formatted for publication.

Title page

Spontaneous non-traumatic *Clostridium perfringens* sepsis

Toru Hifumi

Department of Emergency and Critical Care Medicine, St. Luke's International Hospital,
9-1 Akashi-cho, Chuo-ku, Tokyo, 104-8560, Japan

* Corresponding author: **Toru Hifumi**

Department of Emergency and Critical Care Medicine, St. Luke's International Hospital,
9-1 Akashi-cho, Chuo-ku, Tokyo, 104-8560, Japan

Tel: +81-3-3541-5151; Fax: +81-3-5550-7066

E-mail: hifumitoru@gmail.com

Running title: Spontaneous sepsis due to *C. perfringens*

Keywords: sepsis; *Clostridium perfringens*; intravascular hemolysis; gas gangrene

Title Page_日本語表記

特発性非外傷性 *Clostridium perfringens* 敗血症

一 二 三 亨

聖路加国際病院 救急部

†責任著者連絡先

一 二 三 亨

〒104-8560 東京都中央区明石町9-1

Tel. 03-3541-5151

Fax. 03-5550-7066

E-mail. hifumitoru@gmail.com

Accepted Manuscript

SUMMARY

Clostridium species are gram-positive, spore-forming, anaerobic rods normally found in the soil and the gastrointestinal tract of humans and animals. Spontaneous sepsis due to *C. perfringens* is not caused by injury, which sets it apart from classic gas gangrene that typically follows trauma. Spontaneous *C. perfringens* sepsis often develops as a rapidly progressive intravascular hemolysis and metabolic acidosis, with high mortality rates of over 70% with standard intensive care. In such cases, alpha-toxin secreted by *C. perfringens* is considered as the main toxin responsible for intravascular hemolysis, disseminated intravascular coagulopathy, and multiple organ failure. Theta-toxin causes a cytokine cascade which results in peripheral vasodilation similar to that seen in septic shock. For *C. perfringens* infections, antibiotics, such as high-dose penicillin, and surgical drainage as early as possible are the principal treatments of choice. However, considering the current mortality rate of sepsis, outcomes have not improved with the current standard treatment for *C. perfringens* infections. Monoclonal antibody against theta-toxin in combination with gas gangrene antitoxin are promising therapeutic options.

1. Introduction

Clostridium perfringens is a gram-positive, anaerobic bacterium that grows in the gastrointestinal tract of humans and animals and is found soil (1). Spontaneous *C. perfringens* sepsis is not caused by injury, which sets it apart from classic gas gangrene that typically follows trauma. Spontaneous sepsis due to *C. perfringens* often presents as a rapidly progressive intravascular hemolysis and metabolic acidosis, with high mortality rates of above 70% with standard intensive care (2-11). In these cases, alpha-toxin secreted by *C. perfringens* is considered to be the main toxin, which is responsible for intravascular hemolysis, disseminated intravascular coagulopathy (DIC) (12, 13), and multiple organ failure. Although the number of reported cases with spontaneous *C. perfringens* sepsis is increasing (14-27), appropriate treatment strategies have not been established.

In this review, we aim to clarify the pathophysiology and diagnosis of spontaneous *C. perfringens* sepsis and to provide insights regarding treatment strategies including antitoxin therapy.

2. Pathophysiology

At least 12 toxins are produced by *C. perfringens* types *A*, *B*, *C*, *D*, and *E*, with alpha,

beta, epsilon, and iota as the major toxins (28). Recently, a French group was the first to report the case of a patient with septic shock due to peritonitis caused by *C. perfringens*; the case was complicated by massive hemolysis secondary to the secretion of alpha-toxin and theta-toxin by the bacterium (29). Alpha-toxin is a phospholipase C lecithinase that degrades phospholipids in the erythrocyte membrane, leading to subsequent accelerated destruction (14, 30). Phospholipase C lecithinase may also cause platelet destruction, leading to thrombocytopenia. Conversely, theta-toxin is a cholesterol-dependent cytolysin that forms transmembrane pores; it also inhibits chemotaxis and the organized aggregation of neutrophilic granulocytes (29). Additionally, both alpha-toxin and theta-toxin affect the circulatory system. Specifically, alpha-toxin directly inhibits myocardial contractility whereas theta-toxin induces significant peripheral vasodilation (31). These toxic effects explain the characteristic fulminant shock observed in severe *C. perfringens* infection. The simultaneous presence of both toxins, which act synergistically, is necessary for the development of serious *C. perfringens* infections (31, 32). Thus, alpha-toxin and theta-toxin are considered as the principal virulence factors of *C. perfringens* infection.

3. Diagnosis

Hemolysis is the first alarming sign of *C. perfringens* infection. The presence of a liver abscess with gas formation, accompanied with the signs of hemolysis, such as increased levels of indirect bilirubin and lactate dehydrogenase, and anemia are typical manifestations; however, progression to gross hemolysis usually leads to death (**Figure 1**) (33, 34). Therefore, rapid diagnosis is essential, and definitive diagnosis before the patient progresses to gross hemolysis is crucial. Considering the pathophysiology of *C. perfringens* infection, early detection of alpha-toxin and theta-toxin in the serum might be the key for diagnosis. Monoclonal antibodies against these toxins, which have already been used in research settings, might be utilized for the development of diagnostic assays. Clinicians should always suspect *C. perfringens* sepsis in the absence of overt signs of hemolysis in patients with liver abscesses accompanied with gas formation.

In addition to the analysis for the presence of toxins, the diagnosis of DIC is also important for deciding on whether adjunctive therapy should be initiated. The diagnosis of DIC is based on the criteria established by the Japanese Association for Acute Medicine (35, 36), with a total score ≥ 4 indicating DIC.

4. General treatment strategies and adjunctive therapies

For the bacterial infection, antibiotics, such as high-dose penicillin, and surgical drainage

as early as possible are the two main treatments of choice (30). However, considering the high mortality rate of sepsis (37), the currently utilized standard treatments for *C. perfringens* infection have not led to better outcomes. To further improve the patient outcomes, focusing on specific treatments is a reasonable first step in establishing therapeutic strategies with acceptable clinical outcomes.

Recombinant human soluble thrombomodulin (rTM) has been shown as effective for sepsis-induced DIC in a meta-analysis (38). We previously examined the effects of rTM on hemolysis, coagulation status, inflammation, and mortality in α -toxin-treated rats (39) and found that rTM improved coagulation response induced by α -toxin with a significant difference in FDP level and platelet count in the rTM-treated group compared with the α -toxin-only group (39). These results suggest rTM as a candidate for the treatment of *C. perfringens*-induced DIC because it serves as a negative feedback regulator of blood coagulation (40).

Recently, Kubo *et al.* reported two patients with liver abscesses caused by *C. perfringens* who were initiated on intensive plasma exchange and survived (41). The application of plasma exchange to remove excess toxins produced by *C. perfringens* is reasonable. In fact, patients with Yamakagashi snake bites survived with aggressive plasma exchange therapy (42). However, in the real-world clinical settings, especially for

patients in septic shock, dialysis may cause severe hypotension, which may necessitate therapy suspension. Thus, alternative therapies should be considered in patients with septic shock due to *C. perfringens*.

5. Antitoxin therapy

The gas gangrene antitoxin, developed against the toxins produced by *C. perfringens* type A, *C. septicum*, and *C. oedematiens*, has been used as a treatment option for classic gas gangrene following trauma. However, this product is no longer available in the United States due to poor efficacy and severe allergic reactions. The gas gangrene antitoxin can neutralize α -toxin secreted by *C. perfringens*. Therefore, we have introduced and strongly recommended the use of the gas gangrene antitoxin as the optimal therapy in *C. perfringens* sepsis based on the pathophysiological mechanism (34, 43, 44). In a study investigating the effects of gas gangrene antitoxin on hemolysis, coagulation status, inflammation, and mortality in α -toxin-treated rats, we demonstrated that the gas gangrene antitoxin could stop hemolysis via the neutralization of α -toxin (39).

In a clinical setting, Yoshida *et al.* is the first to report a patient with *C. perfringens* sepsis who was treated with the gas gangrene antitoxin (45). However, the efficacy of the gas gangrene antitoxin remains unknown because it was administered after the patient

developed cardiopulmonary arrest and the patient died eight hours after the gas gangrene antitoxin administration.

The gas gangrene antitoxin is owned by the government under the name of Kokuyu vaccine (34) and stored at nine institutions that are spread across Japan. Therefore, rapid administration of the gas gangrene antitoxin is not practical due to the supply limitations. In the future, the gas gangrene antitoxin stocks at major hospitals such as the university hospitals and national hospital organizations should be considered to treat patients with spontaneous *C. perfringens* sepsis.

The clinical use of the monoclonal antibody against theta-toxin, developed and defined first by Sato *et al.* (46), in combination with the gas gangrene antitoxin is a promising therapeutic approach for spontaneous *C. perfringens* sepsis.

6. Prevention

Considering the high mortality rate with the currently used standard therapy, prevention strategies may be more practical than the development of promising monoclonal antibodies. As the first step for prevention, vaccination is considered as a principal component. Four doses of the diphtheria/tetanus/pertussis vaccine are administered during infancy, and a vaccine against diphtheria and tetanus is administered at the age of

11–12 years under the Preventive Vaccination Law enacted in 1968 in Japan; this led to the disappearance of the diphtheria infection from clinical practice (47, 48). Currently, there are no licensed vaccines which are suitable for protection against *C. perfringens* sepsis in humans (49). However, vaccines that are currently in development for use in animals can potentially be developed further for use in humans (49, 50). Therefore, vaccination might be considered as an effective strategy to protect from serious *C. perfringens* sepsis in humans.

7. Future considerations

There is no nationwide registration for *C. perfringens* sepsis in Japan. Therefore, the exact number of patients with *C. perfringens* sepsis remains unknown. We recently launched a research group supported by the Research Program on Emerging and Re-emerging Infectious Disease of the Japan Agency for Medical Research and Development, with the aim to examine spontaneous *C. perfringens* sepsis in 2019. The creation of a nationwide registry for *C. perfringens* sepsis is the first step for the establishment of effective treatment strategies, and further urgent work will be required.

8. Conclusion

In this review, we provided an overview of the pathophysiology and the diagnosis of spontaneous *C. perfringens* sepsis and provided the currently utilized treatment strategies including the gas gangrene antitoxin, which can be administered as early as possible in combination with antibiotics to neutralize the toxins.

Acknowledgements

This research was supported by the Research Program on Emerging and Re-emerging Infectious Disease from the Japan Agency for Medical Research and Development (AMED).

Conflict of Interest

None to declare

References

1. Fraser AG, Collee JG. The production of neuraminidase by food poisoning strains of *Clostridium welchii* (*C. perfringens*). *J Med Microbiol*. 1975;8:251-63.
2. Ng H, Lam SM, Shum HP, et al. *Clostridium perfringens* liver abscess with massive haemolysis. *Hong Kong Med J*. 2010;16:310-2.
3. Rogstad B, Ritland S, Lunde S, et al. *Clostridium perfringens* septicemia with massive hemolysis. *Infection*. 1993;21:54-6.
4. Simon TG, Bradley J, Jones A, et al. Massive intravascular hemolysis from *Clostridium perfringens* septicemia: a review. *J Intensive Care Med*. 2014;29:327-33.
5. Vaiopoulos G, Calpadaki C, Sinifakoulis H, et al. Massive intravascular hemolysis: a fatal complication of *clostridium perfringens* septicemia in a patient with acute myeloid leukemia. *Leuk Lymphoma*. 2004;45:2157-9.
6. Landi G, Gualtieri G, Bello IS, et al. A case of fatal *Clostridium perfringens* bacteremia and sepsis following CT-guided liver biopsy of a rare neuroendocrine hepatic tumor. *Forensic Sci Med Pathol*. 2017;13:78-81.
7. Kwon O, Kim HY, Uh Y, et al. A Case of *Clostridium perfringens* Septicemia with Fatal Hemolytic Complication. *Korean J Lab Med*. 2006;26:358-61.
8. Kirchhoff P, Muller V, Petrowsky H, et al. Fatal emphysematous cholecystitis caused by *clostridium perfringens*. *Surgery*. 2007;141:411-2.
9. Takemura K, Sekoguchi S, Yamane S, et al. A case of a gas-forming liver abscess caused by *Clostridium perfringens* after transcatheter arterial chemoembolization. *Nihon Shokakibyo Gakkai Zasshi*. 2018;115:554-62. Japanese.
10. Tabarelli W, Bonatti H, Cejna M, et al. *Clostridium perfringens* liver abscess after pancreatic resection. *Surg Infect (Larchmt)*. 2009;10:159-62.
11. Vuolio S, Vahakari M, Laurila J, et al. Liver abscess and sepsis caused by *clostridium perfringens*. *Duodecim*. 2016;132:1904-7.
12. Ito M, Takahashi N, Saitoh H, et al. Successful treatment of necrotizing fasciitis in an upper extremity caused by *Clostridium perfringens* after bone marrow transplantation. *Intern Med*. 2011;50:2213-7.
13. Daly JJ, Haeusler MN, Hogan CJ, et al. Massive intravascular haemolysis with T-activation and disseminated intravascular coagulation due to clostridial sepsis. *British journal of haematology*. 2006;134:553.
14. Hashiba M, Tomino A, Takenaka N, et al. *Clostridium Perfringens* Infection in a Febrile Patient with Severe Hemolytic Anemia. *Am J Case Rep*. 2016;17:219-23.
15. Sarvari KP, Vasas B, Kiss I, et al. Fatal *Clostridium perfringens* sepsis due to

- emphysematous gastritis and literature review. *Anaerobe*. 2016;40:31-4.
16. Yamaguchi R, Makino Y, Chiba F, et al. Fatal *Clostridium perfringens* septicemia suggested by postmortem computed tomography: A medico-legal autopsy case report. *Forensic Sci Int*. 2015;253:e4-9.
 17. Shindo Y, Dobashi Y, Sakai T, et al. Epidemiological and pathobiological profiles of *Clostridium perfringens* infections: review of consecutive series of 33 cases over a 13-year period. *Int J Clin Exp Pathol*. 2015;8:569-77.
 18. Meinders AJ, Dijkstra I. Massive hemolysis and erythrophagocytosis in severe sepsis. *Blood*. 2014;124:841.
 19. Kyang LS, Bin Traiki TA, Alzahrani NA, et al. Microwave ablation of liver metastasis complicated by *Clostridium perfringens* gas-forming pyogenic liver abscess (GPLA) in a patient with past gastrectomy. *Int J Surg Case Rep*. 2016;27:32-5.
 20. Garcia Carretero R, Romero Brugera M, Vazquez-Gomez O, et al. Massive haemolysis, gas-forming liver abscess and sepsis due to *Clostridium perfringens* bacteraemia. *BMJ Case Rep*. 2016;2016.
 21. Rives C, Chaudhari D, Swenson J, et al. *Clostridium perfringens* liver abscess complicated by bacteremia. *Endoscopy*. 2015;47 Suppl 1 UCTN:E457.
 22. Eltawansy SA, Merchant C, Atluri P, et al. Multi-organ failure secondary to a *Clostridium perfringens* gaseous liver abscess following a self-limited episode of acute gastroenteritis. *Am J Case Rep*. 2015;16:182-6.
 23. Kusumoto K, Hamada A, Kusaka T, et al. A patient with sepsis and a gas-forming liver abscess caused by *Clostridium perfringens* treated with continuous perfusion drainage. *Nihon Shokakibyo Gakkai Zasshi*. 2014;111:1416-23. Japanese.
 24. Imai J, Ichikawa H, Tobita K, et al. Liver abscess caused by *Clostridium perfringens*. *Intern Med*. 2014;53:917-8.
 25. Oshima S, Takaishi K, Tani N, et al. Two cases of liver abscess caused by *Clostridium perfringens* after transcatheter arterial chemoembolization. *Gan To Kagaku Ryoho*. 2013;40:1795-7. Japanese.
 26. Qandeel H, Abudeeb H, Hammad A, et al. *Clostridium perfringens* sepsis and liver abscess following laparoscopic cholecystectomy. *J Surg Case Rep*. 2012;2012:5.
 27. Law ST, Lee MK. A middle-aged lady with a pyogenic liver abscess caused by *Clostridium perfringens*. *World J Hepatol*. 2012;4:252-5.
 28. McDonel JL. *Clostridium perfringens* toxins (type A, B, C, D, E). *Pharmacol Ther*. 1980;10:617-55.
 29. Pastene B, Gregoire E, Blasco V, et al. [Alpha and theta toxin *Clostridium perfringens* infection complicated by septic shock and hemolysis]. *Ann Fr Anesth Reanim*.

- 2014;33:552-3. French.
30. van Bunderen CC, Bomers MK, Wesdorp E, et al. Clostridium perfringens septicaemia with massive intravascular haemolysis: a case report and review of the literature. *Neth J Med.* 2010;68:343-6.
 31. Ellemor DM, Baird RN, Awad MM, et al. Use of genetically manipulated strains of Clostridium perfringens reveals that both alpha-toxin and theta-toxin are required for vascular leukostasis to occur in experimental gas gangrene. *Infect Immun.* 1999;67:4902-7.
 32. Awad MM, Ellemor DM, Boyd RL, et al. Synergistic effects of alpha-toxin and perfringolysin O in Clostridium perfringens-mediated gas gangrene. *Infect Immun.* 2001;69:7904-10.
 33. Shoko T, Urushibata N, Murata K. A case of small bowel necrosis due to clostridium perfringens infection rapidly followed a fatal course. *Rinsho Geka* 2016;77:1098-104. Japanese.
 34. Hifumi T, Yamamoto A, Ato M, et al. Clinical Serum Therapy: Benefits, Cautions, and Potential Applications. *Keio J Med.* 2017;66:57-64.
 35. Gando S, Saitoh D, Ogura H, et al. Disseminated intravascular coagulation (DIC) diagnosed based on the Japanese Association for Acute Medicine criteria is a dependent continuum to overt DIC in patients with sepsis. *Thromb Res.* 2009;123:715-8.
 36. Singh RK, Baronia AK, Sahoo JN, et al. Prospective comparison of new Japanese Association for Acute Medicine (JAAM) DIC and International Society of Thrombosis and Hemostasis (ISTH) DIC score in critically ill septic patients. *Thromb Res.* 2012;129:e119-25.
 37. Raith EP, Udy AA, Bailey M, et al. Prognostic Accuracy of the SOFA Score, SIRS Criteria, and qSOFA Score for In-Hospital Mortality Among Adults With Suspected Infection Admitted to the Intensive Care Unit. *JAMA.* 2017;317:290-300.
 38. Yamakawa K, Aihara M, Ogura H, et al. Recombinant human soluble thrombomodulin in severe sepsis: a systematic review and meta-analysis. *J Thromb Haemost.* 2015;13:508-19.
 39. Hifumi T, Nakano D, Chiba J, et al. Combined therapy with gas gangrene antitoxin and recombinant human soluble thrombomodulin for Clostridium perfringens sepsis in a rat model. *Toxicon.* 2018;141:112-7.
 40. Mohri M, Sugimoto E, Sata M, et al. The inhibitory effect of recombinant human soluble thrombomodulin on initiation and extension of coagulation--a comparison with other anticoagulants. *Thromb Haemost.* 1999;82:1687-93.
 41. Kubo T, Kawano Y, Miyanishi K, et al. Two cases of liver abscess caused by Clostridium perfringens that potentially cured by combined modality therapy. *Kanzo.* 2017;58:105-14.

- Japanese.
42. Hifumi T, Sakai A, Kondo Y, et al. Venomous snake bites: clinical diagnosis and treatment. *J Intensive Care*. 2015;3:16.
 43. Hifumi T, Koido Y, Takahashi M, et al. Antitoxin treatment for liver abscess caused by *Clostridium perfringens*. *Clin Mol Hepatol*. 2013;19:97-8.
 44. Hifumi T, Takahashi M, Morokuma K, et al. Do you know the *Clostridium perfringens* antitoxin? . *J Jpn Soc intensive Care Med*. 2010;17:287-9. Japanese.
 45. Yoshida J, Nakamura H, Yamada S, et al. A case of freeze-dried gas gangrene antitoxin for the treatment of *Clostridium perfringens* sepsis. *Nihon Shokakibyo Gakkai Zasshi*. 2015;112:332-8. Japanese.
 46. Yamakawa Y, Ito A, Sato H. Theta-toxin of *Clostridium perfringens*. I. Purification and some properties. *Biochim Biophys Acta*. 1977;494:301-13.
 47. Okada K, Ueda K, Morokuma K, et al. Seroepidemiologic study on pertussis, diphtheria, and tetanus in the Fukuoka area of southern Japan: seroprevalence among persons 0-80 years old and vaccination program. *Jpn J Infect Dis*. 2004;57:67-71.
 48. Takahashi M, Komiya T, Fukuda T, et al. A comparison of young and aged populations for the diphtheria and tetanus antitoxin titers in Japan. *Jpn J Med Sci Biol*. 1997;50:87-95.
 49. Titball RW. *Clostridium perfringens* vaccines. *Vaccine*. 2009;27 Suppl 4:D44-7.
 50. Nagahama M. Vaccines against *Clostridium perfringens* alpha-toxin. *Curr Pharm Biotechnol*. 2013;14:913-7.

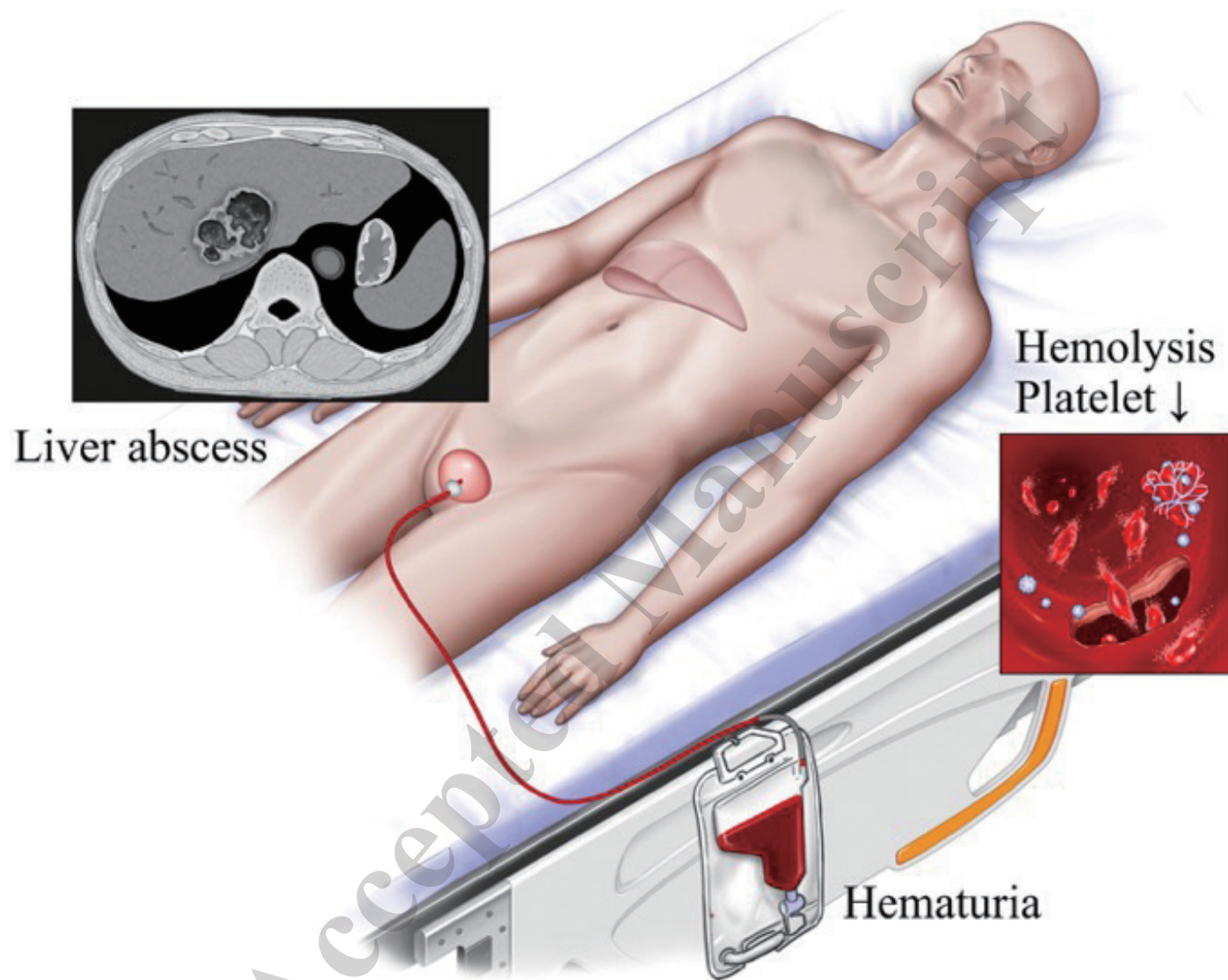


Figure 1. Clinical manifestations of spontaneous, non-traumatic *Clostridium perfringens* sepsis